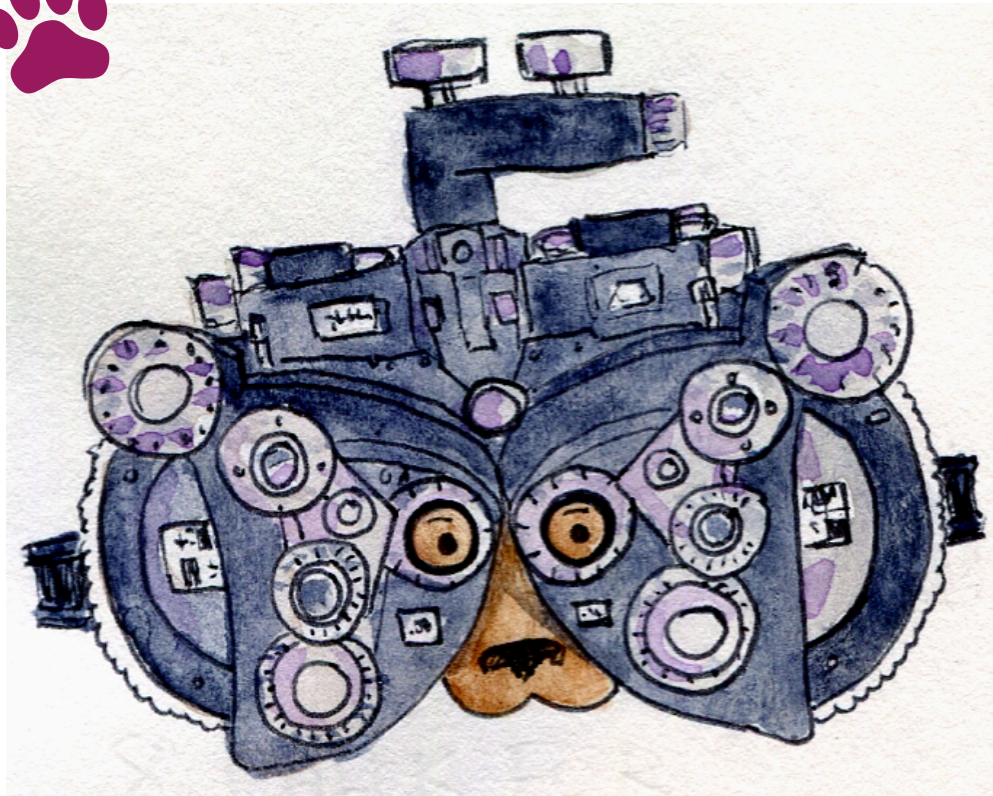




Let's learn eye anatomy with EYE DOGTOR JULIE!



NERVE
PUPIL
VITREOUS
EYELID
LENS
RETINA

CONJUNCTIVA
FOVEA
MACULA
SCLERA
CORNEA
IRIS



by **carmel.md**



Word Scramble

Unscramble each word and write it in the blank provided.

1. dliyee _____
2. noreca _____
3. uiplp _____
4. reslca _____
5. uaitjvonccn _____
6. ntriaa _____
7. muacla _____
8. iisr _____
9. oavfe _____
10. eervn _____
11. lnes _____
12. voritesu _____

